

Research Journal of Pharmaceutical, Biological and Chemical Sciences

An Outcome Analysis Of Distal Femoral - Locking Compression Plate Fixation (DF-LCP) In Comminuted Intra Articular Distal Femur Fractures: Results Of 66 Cases.

A Sivasenthil^{1*}, P Murali², and Renjit John Matthew³, and S Kumaravel⁴.

¹Assistant Professor of Orthopaedics, Department of Orthopaedics, Thanjavur Medical College, Thanjavur, Tamil Nadu, India.

²Assistant Professor Of Orthopedics, Department Of Orthopedics, Thanjavur Medical College, Thanjavur, Tamilnadu, India.

³Former Orthopaedics Post Graduate, Department of Orthopaedics, Thanjavur Medical College, Thanjavur, Tamil Nadu, India.

⁴Professor and HOD of Orthopaedics, Thanjavur Medical College, Thanjavur, Tamil Nadu, India.

ABSTRACT

Comminuted intra articular fractures of the distal femur occurs in both old and young individuals account for 6% of all femoral fractures. Variety of treatment options available for these fractures ranging from total conservation, external fixation to different plates, eg-non locking condylar buttress plate, DCS, locking-DFLCP plate, each with their own merits and demerits. In this study we used distal femur locking compression plate (DF-LCP) fixation by open reduction and internal fixation done in 66 cases which allowed early mobilization and avoids complications with acceptable results even in osteoporotic bones. Results of this study comparable to other series. In conclusion locking compression plate for distal femur is a safe and effective tool to manage these difficult fractures.

Keywords: Distal Femur, Intra articular fracture, DF-LCP.

<https://doi.org/10.33887/rjpbcs/2023.14.5.3>

**Corresponding author*

INTRODUCTION

Distal femur fractures account for 6% of all femoral fractures but are vested with a lot of problems of deforming forces on a small peri-articular fragment which is comminuted and sometimes osteoporotic. The violence is either high velocity injuries in younger individuals or a trivial fall in case of older osteoporotic individuals. Intra articular fractures with bone loss with prolonged immobilization can cause poor cartilage nutrition, knee capsular contraction leading to stiff painful knees. Being near the largest synovial joint, can cause non-union in spite of cancellous bone. There are various methods of fixation in this region with merits and demerits [1]. The objective of this study was to find the effectiveness of DF-LCP for comminuted fractures of distal femur in adults [2-10]

METHODOLOGY

The study was approved by the institutional ethical committee of Thanjavur Medical College. Between June 2011 to September 2019, sixty-six patients with supracondylar and inter condylar fractures of the distal femur treated by open reduction and internal fixation using locking compression plates were included in the study. It is amphisperspective study, done between 2011 and 2019 on the adult patients of both sexes with closed and open grade I comminuted mullers type C intra articular fractures of distal femur treated by open reduction and internal fixation using DF-LCP were selected for inclusion in the study. Those patients with above fractures in whom fixation of the fracture could not be done due to the associated co-morbidities and in patients with severe life threatening or other medical problems were excluded from the study, fractures in paediatric age group, Grade II, III, a,b,c open fractures where external fixation is the best option were also excluded from the study. After sorting out the patients on the basis of the already defined inclusion and exclusion criteria selected patients were briefed about the nature of study and the different surgical options available to them and a written informed consent in their own language was obtained.

According to ATLS protocols treatment started as soon as the patient was received in the trauma ward. Which includes airway and shock management followed by surveying of other systems for injuries splinting in Thomas splint and bedside radiographs were done. A detailed history as to injury, proper systematic clinical examination was done to find out the nature of trauma, mechanism of injury and duration since injury, any associated injuries and local examination of the injured limb to rule out neurovascular status and wounds. After hemodynamic stability a series of radiographs including AP and lateral views of involved thigh and knee and radiographs of the pelvis to rule out ipsilateral neck of femur fracture. AP and lateral radiographs of the uninjured thigh, knee was also obtained for comparison and templating purposes. CT scan of the knee is done to see intra articular fracture depression and compaction with bone loss.

Surgical Procedure

Depending on the fracture either spinal (for isolated distal femur fracture) or spinal cum – epidural (Supracondylar femur fracture with ipsilateral tibia fracture) anaesthesia was given. Patient was positioned supine on a radiolucent table with a bolster under the ipsilateral buttock to allow slight internal rotation of the lower limb Tourniquet was avoided to allow extension of the proximal incision. Broad spectrum antibiotics were given just after spinal anaesthesia. The thigh is draped free and the iliac crest prepared and draped in case bone grafting was required. A sterile sand bag is placed under the knee to facilitate exposure and reduction and to control the flexion of the distal fragment by the pull of the gastrocnemius.

Anterolateral (Swashbuckler incision) curved incision extending from just distal to the middle of the thigh to tibial tuberosity deepened to quadriceps fascia. The vastus lateralis muscle is released from the lateral intermuscular septum and retracted. Lateral para patellar arthrotomy is done to expose the intra articular comminution of fragments. Intra articular fracture fragments were perfectly reduced (with pointed reduction clamps or K- wire as joystick) fixed provisionally with K wires or cancellous screws. Now the fracture is fixed with a locking compression plate of sufficient length and 6.5 mm and 5mm locking cancellous screws distally and 5mm locking cortical screws proximally. Bone grafting was done in 20 cases with severe comminution and bone loss. The released vastus lateralis is closed using interrupted absorbable sutures, the fascia lata is closed using continuous sutures, and the subcutaneous layer is closed with an absorbable suture material and finally skin is closed with surgical staples over a

14-size suction drain. Intravenous broad-spectrum antibiotics continued for 48hours; Suction drain was removed at 48 hours. Static quadriceps exercises and hamstring strengthening exercises were started from the 2nd postoperative day onwards. Gentle hip and ankle mobilisation exercises were started as pain tolerated from 2nd day. staples were removed on the 12th postoperative day.

Continuous passive mobilization leads to satisfactory range of motion, strength and function of the knee joint. It is allowed depending on fractures types and the strength of the fixation If fracture stable then therapy was started early and most useful knee range was obtained In the porotic bone it is delayed for the first few weeks post-operatively however our elderly patients were also mobilise actively in bed in the early post operative period.Non weight bearing with walker support was started in the first week if the fixation was stable. Partial weight bearing was allowed at 8 weeks, full weight bearing was allowed only after radiological evidence of union at the fracture site. Regular clinical and radiological evaluation is done for fracture healing, any change in alignment or screw breakage, Knee motion, Knee function was assessed clinically based on Neer’s rating system, radiological outcome is assessed by serial radiographs.Clinical union is painless fracture site on full weight bearing, Radiological union is bridging trabeculation across the fracture site on three of four cortices. After discharge each patient followed up once in two weeks for the first two months and then monthly interval for next four months, thereafter once in three months for next one year.

RESULTS

The series consists of 61 cases of closed and five cases of open grade I intra articular fractures of the distal femur treated by open reduction and internal fixation using locking compression plates. The following observations were made from the study.

DISCUSSION

Table showing the details of the cases which were studied

Total Number. of. Cases	66 (61 closed and 5 cases of open grade 1 intraarticular fractures)
Males	59 = 89%
Females	7 = 11%
Male female ratio	8 : 1
Wound status	Closed - 61, Grade I open - 5
Mechanism of injury	57- Vehicular accidents in majority of the cases. (86.4%) two wheelers and four wheelers or pedestrian injuries. 5 - Accidental fall from standing height either in their home or while working (7.6%) 3 - Fall from height (4.5%) 1 - wall collapse of house (1.5%)
Fracture pattern based on Muller’s classification	C1 = 7 (10.6%), C2 = 38 (57.6%) C3 = 21 (31.8%)
Implant, method of reduction	open reduction and internal fixation using locking compression plates - DFLCP
Age distribution	18-45 years - High energy trauma 61-75 years - Trivial falls (osteoporotic) 18-30 years = 31 Cases (47%) 31-45 years = 21 Cases (32%) 46-60 years = 10 Cases (15%) 61-75 years = 3 Cases (4.5%) > 75 years = 1 Case (1.5%)
Presentation of maximum injuries	6 pm to early morning 3 am
Mean age for males	34
Mean age for females	61
Side distribution	RIGHT- 36 cases (55%) LEFT-30 cases (45%) marginally more fractureson right for no specific reason

Comorbidities	3 - Type 2 Diabetes Mellitus 2 - Newly diagnosed hypertensive 1 - Lower respiratory tract infection 1 - Post polio residual paralysis in uninjured lower limb
Associated fractures - 15	5 - Ipsilateral both bone leg fracture 2 - Patella fracture 2 - Distal radius fracture 2 - Head injury and facial injuries 1 - Ipsilateral proximal tibia fracture 1 - Both bone forearm fracture 1 - Humerus shaft Fracture 1 - Brachial plexus injury
The mean duration between injury and surgery	11 days
Anaesthesia	Spinal ± epidural Spinal = 58 (88%) Epidural = 8 (12%)
Team of doctors	SK, AS, RJM
Length of incision	distal 10 cm Proximal 5 cm
Bone grafting	20 cases
Implant	DF-LCP
Average time for union 12 to 16wks	10 - 12 wks = 3 (4.6%) 12 - 14 wks = 35 (53%) 14 - 16 wks = 21 (31.8%) 18 wks = 7 (10.6%)
Average duration of surgery	55 minutes in average. Shortest time -40 minutes. Longest time 1 hour 30 minutes
Blood transfusion	Needed in 50 % cases for Hb %less than 10 gms %
Secondary procedures	1
Mean follow up	All 66 cases were followed up for a period of 8 months to 24 months
Lost for follow up	Nil
Clinical assessment by Neer's rating criteria taking into account pain, knee range of motion, angulations and functional ability,	27 excellent - (41%) 20 good - (30%) 12 fair- (18%) 7 poor results - (11%) Poor result=treatment failures as they were not able to walk and had pain at rest.
Radiological outcome	Excellent 30 (45.5%) Good 20 (30%) Acceptable 11 (17%) poor in 5(7.5%)
Complications	Post-operative knee stiffness in - 21cases (31.8%) Infection - 7 cases (10.6%) Shortening - 7 Cases (10.6%) Delayed Union - 6 Cases (9%) Bent implant - 1case (1.5%)
Average duration of hospital stay	4 weeks

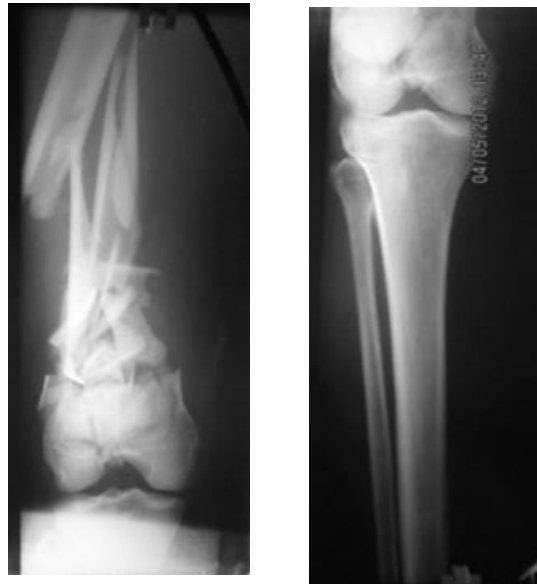This series consists of 66 cases closed and grade I intraarticular fracture of the distal femur treated by open reduction and internal fixation using locking compression plates. In this study, Out of the 66 Patients 59 were males making up 89% of the cases and 7 were females making up the remaining 11 %, male to female ratio was almost 8 : 1 most of the patients in this study were young patients in the age group 18- 30 and 31 45 yrs. The cause of injury in this subgroup of patients is attributed to high energy trauma. The side distribution in this study showed a marginally a greater number of persons with fractures on the right side than on the left. We could not find any specific reason for this. Most of these fractures presented from 6 pm to early morning 3am none of the patients had bilateral fractures. Two patients had associated fracture of the distal radius and patella; five patients had an associated fracture of both bones of the same leg. Associated proximal tibia fracture, both bones forearm fracture, Humerus shaft fracture, brachial plexus injury was noted in one patient each respectively. Head injury and facial

injury were seen in two cases which resulted in delay of definitive fixation in these patients. No patient died during the course of this study.

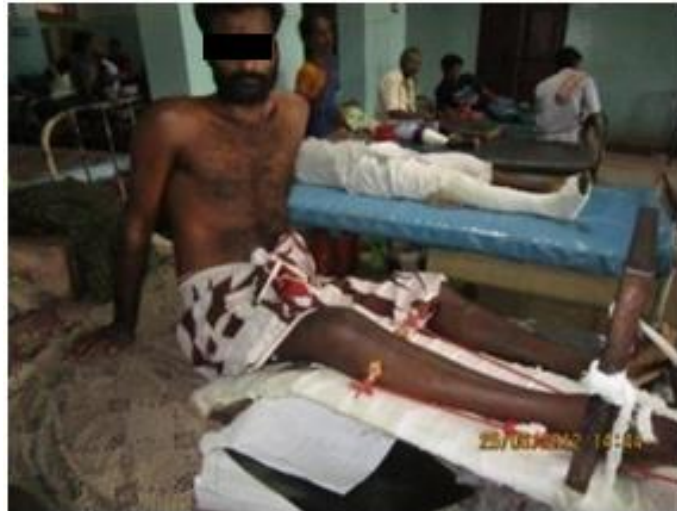Three were known cases of type II diabetes mellitus and two cases were newly diagnosed as hypertensive's One patient had a lower respiratory tract infection due to which the case was delayed. One patient had post-polio residual paralysis in the uninjured lower limb. In this study 57 patients who constituted the major chunk were injured as a result of a vehicular accident which included both two wheelers and four wheelers or pedestrian injuries. Three patients were injured as a result of fall from height and five cases as a result of accidental fall from standing height either in their home or while working. One patient was injured as a result of wall collapse in his house, 38 of the cases were Muller type C2, 21 were type C3 and 7 were type C1. Complications included postoperative knee stiffness in almost 31.8 % of the patients, 10.6% of the cases got infected, six cases went in for delayed union. There was a case of bent implant in a patient with premature weight bearing and this patient was taken up for revision surgery and the bend was corrected using bending irons and bone grafting was done, she later progressed to union. limb length discrepancy in the form of shortening less than 2.5cm was seen in six patients and significant shortening more than 5cm was seen in one patient. In this study by the analysis of the results using the Neer's rating criteria taking into account pain knee range of motion angulation and functional ability, there were 27 cases with excellent results, 20 cases with good results and twelve cases with fair results. Seven cases considered to have had poor results or treatment failures as these patients were not able to walk and had pain at rest. The management of supracondylar fractures now has a better outcome due to improved biomechanics of the implants. However, the new methods are not without complications. All patients survived the course of this study [11-20].

CONCLUSION

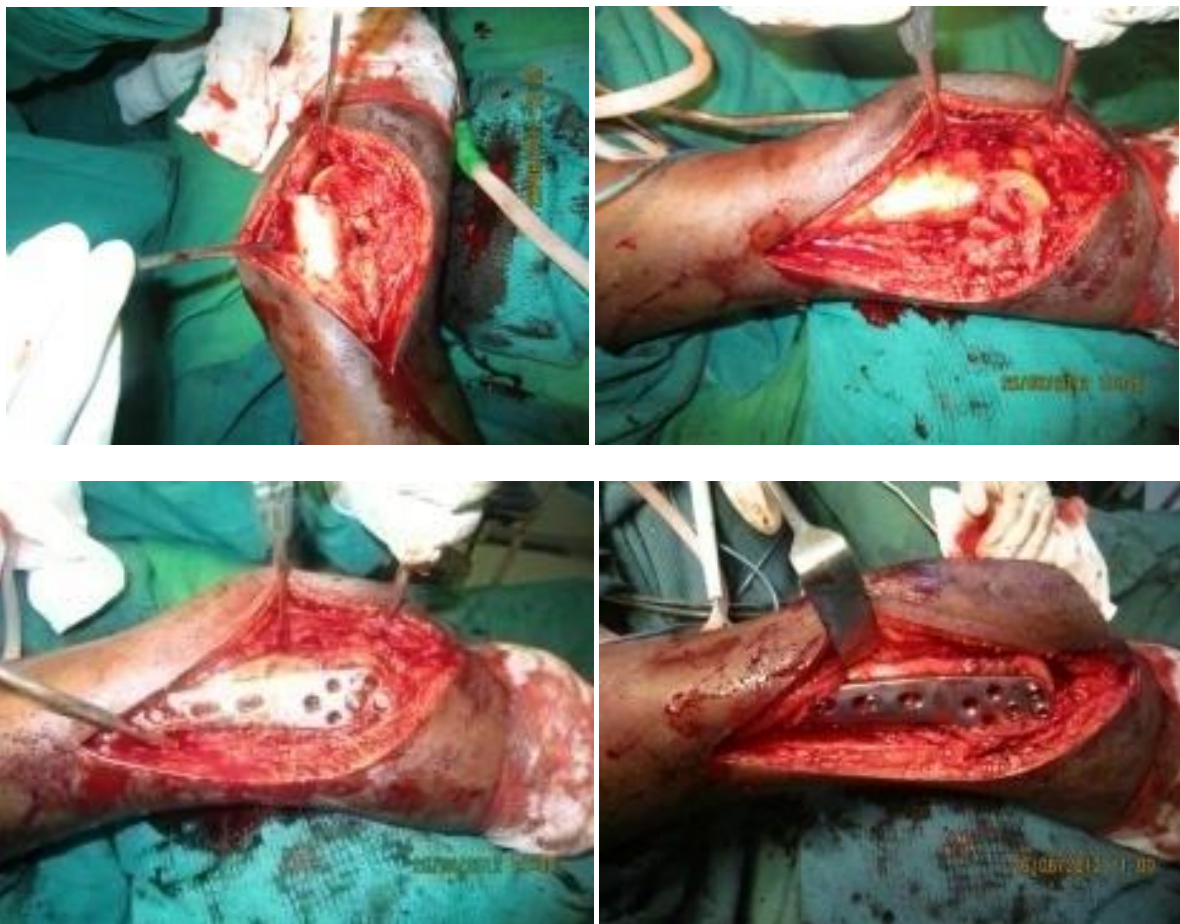
Rigid Fixation of comminuted distal femoral fractures in young person's or in osteoporotic Bone with locking compression plate maintains reduction by anchorage on the fractured fragments and which when applied with meticulous soft tissue handling permits vigorous early knee mobilisation. This results in functional rehabilitation of the patient to an ultimate union. This procedure ensures congruency and length avoids malunion knee stiffness shortening, non-unions using the same implant. To conclude the locking compression plate for distal femur fracture is a safe and effective tool to manage these difficult fractures.



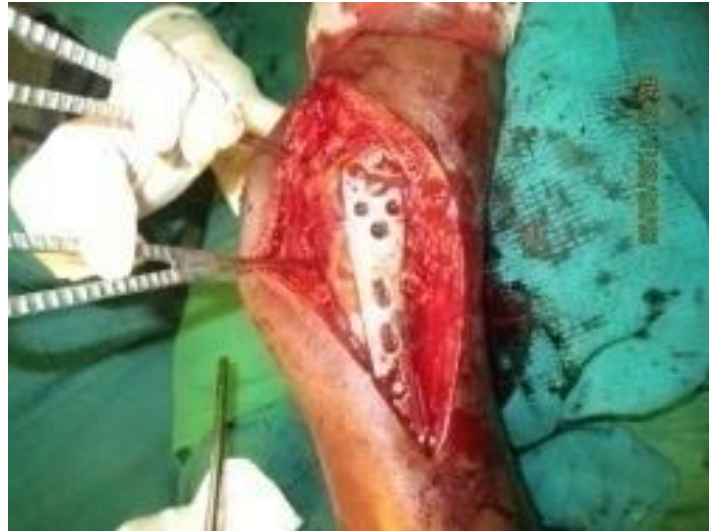Pre operative x-Ray



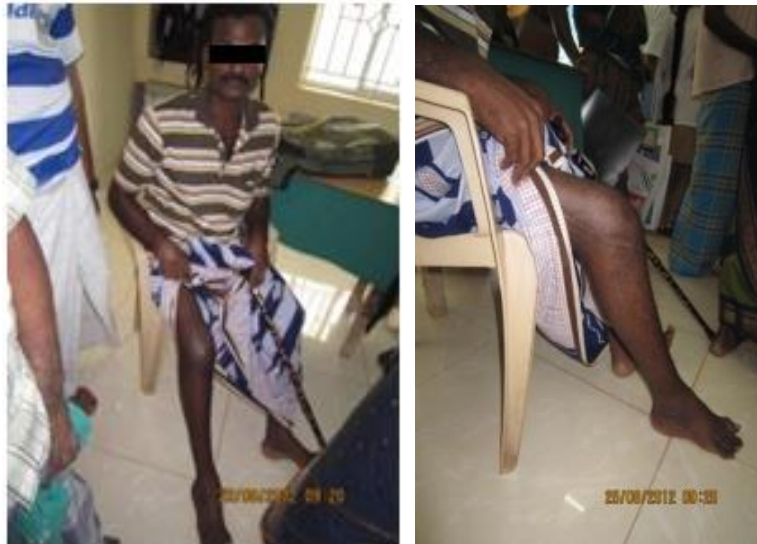Clinical photo



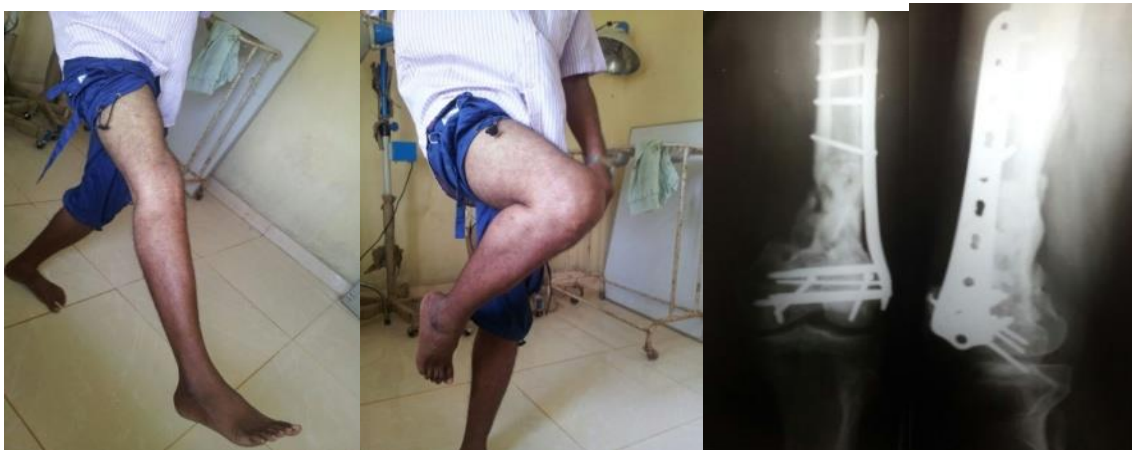Intraoperative photographs



Intraoperative photographs



Immediate Postoperative Clinical photo



20 Weeks Follow Up

REFERENCES

- [1] Kumaravel S, ManoharanM. Is the Dynamic Condylar Screw System Effective in Fractures of Distal Femur. *Res JPharm Biol Chem Sci* 2015; 6(2):1247-54
- [2] George Petsatodis et al. Condylar buttress plate versus fixed angle condylar blade plate versus dynamic condylar screw for supracondylar intra-articular distal femoral fractures. *Journal of Orthopaedic Surgery* 2010;18(1):35-8
- [3] A Saw, CP Lau. Supracondylar nailing for distal femur fractures. *Journal of Orthopaedic Surgery* 2003;11(2);141-147
- [4] P Kanabar, V Kumar, PJ Owen. Less invasive stabilisation system plating for distal femoral fractures. *Journal of Orthopaedic Surgery* 2007;15(3):299-302
- [5] David SM, Eric SI, Keith MP, Zickel. Supracondylar nailing for supracondylar femoral fractures in elderly or infirm patients. *J Bone Joint Surg(Br)* 1994;76-B;596-601
- [6] KD Shelbourne and FR Brueckmann. Rush pin fixation of supracondylar and intercondylar fractures of the femur. *J Bone Joint Surg Am.* 1982;64:161-169
- [7] MS Butler, RJBrumback , TS Ellison , A Poka, GH Bathon, AR Burgess. Interlocking intramedullary nailing for ipsilateral fractures of the femoral shaft and distal part of the femur. *J Bone Joint SurgAm*1991;73:1492-1502
- [8] Matthew R Bong , Kenneth AE, Kenneth JK, Frederick JK, Edward TS, Kazuholesaka, Jordi Bayer , Paul ED. Comparison of the LISS and a retrograde inserted supracondylar intramedullary nail for fixation of a periprosthetic distal femur fracture proximal to a total knee arthroplasty. *The Journal of Arthroplasty* 2002; 7:7.
- [9] Jun-Wen Wang and Lin Hsiu Weng. Treatment of distal femoral non union with internal fixation, cortical allograft struts and autogenous bone grafting. *The Journal Of Bone and Joint Surgery* vol85-A, no.3, March 2003
- [10] Bulhofner, Brett R, Carmen, Barbara, Clifford, Philip. The results of open reduction and internal fixation of distal femur fractures using a biological (indirect) reduction technique.
- [11] Ali Turgay, Mehmet Hakan, Veysel ED. The use of a low profile Ilizarov external fixator in the treatment of complex fractures and non union of the distal femur, *Acta F OrthopBelg* 2009;75:209-218
- [12] LJ Ramesh, SA Rajkumar, R Rajendra, HP Rajagopal. Ilizarov ring fixation and fibular strut grafting for C3 distal femoral fractures. *Journal of Orthopaedic Surgery* 2004;12(1);91-95
- [13] MArazi, R Memik, TC Ogun, MYel. Ilizarov external fixation for severely comminuted supracondylar and intercondylar fractures of the distal femur. *Journal of Bone and Joint Surgery* 2001;83-B:5.
- [14] JM Siliski , M Mahring , HP Hofer. Supracondylar-intercondylar fracture of the femur, treatment by internal fixation. *Journal of Bone and Joint Surgery Am*1989;71;95-104.
- [15] RD Mize, RW Bucholz, DP Grogan. Surgical treatment of displaced, comminuted fractures of the distal end of the femur. *Journal of Bone and Joint Surgery Am*1982;64;871-879.
- [16] JB Giles, JC DeLee, JD Heckman, JE Keever. Supracondylar –Intercondylar fractures of the femur treated with a supracondylar plate and lag screw. *Journal of Bone and Joint Surgery Am*1982;64;864-870.
- [17] Edward T Su, Hargovind DeWal, Paul E Di Cesare. Periprosthetic femoral fractures above total knee replacements. *Journal of the American Academy of Orthopaedic Surgeons* 2004;12(1).
- [18] Laurence M O'Connor Read, Jerome AD, Benjamin MD, Michael GM, Pal Smirthwaite. Comparative endurance testing of the Biomet Matthews Nail and the Dynamic Compression Screw, in simulated condylar and supracondylar femoral fractures. *Biomedical Engineering Online* 2008;7:3
- [19] BR Moed, JT Watson, Retrograde intramedullary nailing, without reaming, of fractures of the femoral shaft in multiply injured patients. *Journal of Bone and Joint Surgery Am*1995;77;1570-1577.
- [20] Awal Hakeem, NajiullahKhan , Mohammad Imran Khan , Faheecmullah. Dynamic condylar screw (DCS) fixation in the treatment of supracondylar fracture of distal femur. *Rawal Medical Journal* 2010;35(1).